


MULTIFETAL GESTATION – MCDA TWINS

Week 72

Prepared by: **Hemangi P Shukla, DO,MS**

Homework Assignment:
SASGOG Pearls of Excellence: Antepartum
Management of Dichorionic/Diamniotic Twins
<https://excellence.org/list-of-pearls/monochorionic-twins/>
(Available as PDF or Podcast)



LEARNING OBJECTIVES



- To review how a monochorionic-diamniotic gestation is diagnosed, including the relationship between zygosity and chorionicity
- To understand the vital role of ultrasound throughout the antepartum course of an MCDA pregnancy
- To be familiar with complications unique to MCDA twin gestations
- To review the recommendations regarding timing and route of delivery for MCDA twins



CASE VIGNETTE

- A 33y G2P0010 woman at 10 weeks EGA by LMP presents for new prenatal care visit. She reports frequent nausea and vomiting. She is able to tolerate fluids and light snacks. She has no other complaints.
- She states she was evaluated 1 month ago at an outside ED for some cramping. She was told she might be having twins because “they saw two sacs” on the ultrasound.



FOCUSED HISTORY

What elements of this patient's history are most relevant?

- POB: **1 sab (managed with medication)**
- PGYN: **Regular menses**; No STI/Cysts/Fibroids; No abnormal paps
- PMH: Denies
- PSH: Denies
- Meds: PNV
- All: NKDA
- Soc: No toxic habits; Lives with her husband; Accepts blood products
- FHx: No hx gyn cancers; No hx DM or HTN; **No hx twins**



PERTINENT PHYSICAL EXAM FINDINGS

What elements of the patient's physical exam are most important?

- VS: P 76 **BP 118/72** Wgt: 65kg Hgt: 160cm BMI: 25
- Cor: Regular rhythm, no M
- Pulm: CTAB b/l
- Abd: Soft, NT/ND, +BS x 4Q
- Pelvic: Vulva: Normal external female genitalia; No lesions
 Vagina: Healthy-appearing mucosa, No discharge
 Cervix: Parous os; L/C/P
 Uterus: NT, ~12-14wk size, anteverted
 Adnexa: No mass/tenderness b/l
- Ext: No calf tenderness b/l; no edema b/l; +1 DTR b/l



DIFFERENTIAL DIAGNOSIS

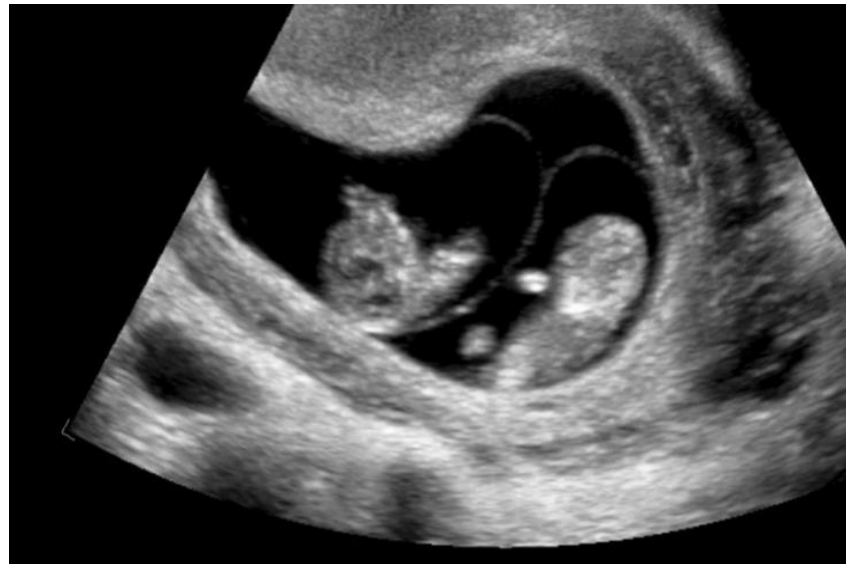What is your differential diagnosis?

- DCDA pregnancy
- MCDA pregnancy



ULTRASOUND

You do a bedside ultrasound and see this image. What is your diagnosis?



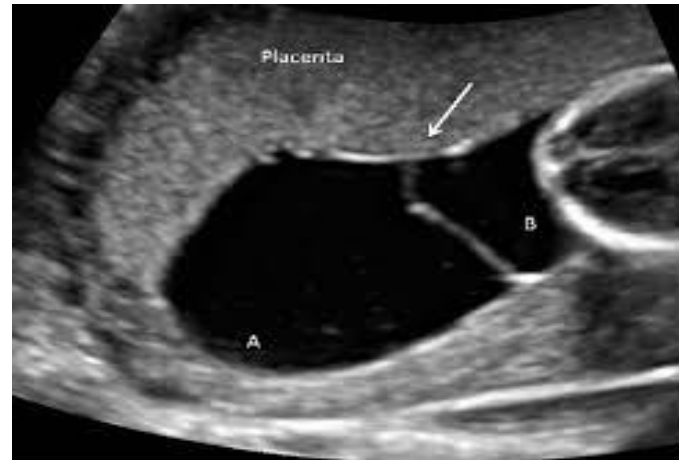- Monochorionic-Diamniotic twin gestation



DIAGNOSIS

What is the best ultrasonographic characteristic to diagnose a monochorionicity?

- T-sign



There is no chorionic tissue extending into the inter-twin membranes



ZYGOSITY

How does timing of embryo splitting correlate with classification of chorionicity-amnionicity of monozygous twins?

Days after fertilization

2-3

3-8

8-13

Classification

Dichorionic-Diamniotic (DCDA)

Monochorionic-Diamniotic (MCDA)

Monochorionic-Monoamniotic (MCMA)

Reminder from another Bon-bon: 25-30% of monozygous twins are DCDA gestations!



IMAGING

You order an official ultrasound to confirm dating & chorionicity, and a NT as part of aneuploidy screening. What is an important factor when interpreting NT measurements in a monochorionic gestation?

- Twins with monochorionic placentation have **increased NT measurements** compared with dichorionic twins
 - Higher likelihood of **structural abnormalities** in identical twins
 - **20%** difference in NT measurements ☐ increased risk of developing **severe TTTS** or fetal death



IMAGING

In addition to an anatomy scan at 18-20 weeks EGA, what is an important consideration in the evaluation of this MCDA gestation?

- Fetal echocardiography at 18-22 weeks gestation

Why is this important?

- Congenital heart disease is more common in monochorionic twins



ANTENATAL SURVEILLANCE

Your patient asks, “How often should I expect to have ultrasounds?”

- Surveillance usually begins at 16 weeks
- You will then have an ultrasound every 2 weeks until 32 weeks
- After that, you will have an ultrasound weekly until delivery

How often should growth assessment be performed?

- Every **3 to 4 weeks**

These visits should include cervical length until 24 weeks EGA



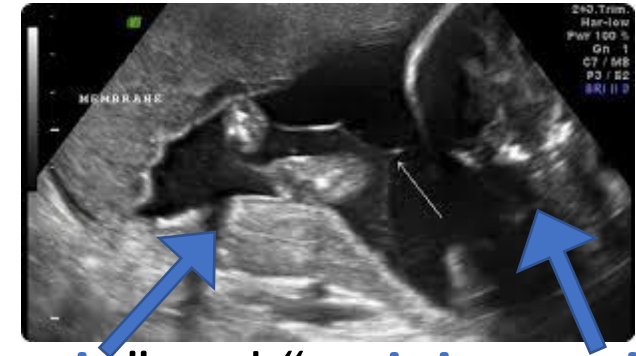
COMPLICATIONS

What are some complications unique to monochorionic twins?

- **Twin-twin transfusion syndrome (TTTS)**

- Blood flow imbalance in placental anastomoses
- U/S

- **Amniotic fluid discordance** between “**donor twin**” and “**recipient twin**”



- **Twin anemia-polycythemia sequence (TAPS)**

- Similar etiology to TTTS, but small anastomoses, so less fluid discordance
- Anemia of donor twin-Polycythemia of recipient twin
- U/S

- **MCA doppler discordance**

- Placental appearance has Hyperechoic (Donor) region – Normal (Recipient) region



COMPLICATIONS

Selective fetal growth restriction (sFGR)

- Usually resulting from unequal placental sharing >> abnormal PCI
- U/S
 - EFW Discordance $\geq 25\%$ + EFW $< 10^{\text{th}}$ percentile in small twin

Twin reversed arterial perfusion sequence (TRAPS)

- Living twin perfuses non-living acardiac twin
- Rare



DELIVERY PLANNING

At what gestational age should patients with uncomplicated MCDA twin gestations undergo delivery?

- Delivery of MCDA twins should occur between **34 – 37 6/7 weeks EGA**

Should vaginal delivery be considered when planning delivery of MCDA twins?

- Vaginal delivery is a reasonable option and should be considered if:
 - **≥32 0/7** weeks of gestation
 - **Presenting** fetus is **vertex**, regardless of presentation of second twin
 - An obstetrician with **experience in internal podalic version** and **vaginal breech delivery** is available



SOCIAL DETERMINANTS OF HEALTH

2014 - Study seeking to uncover the occurrence of complex social processes (or lack thereof) in American obstetrics and their effect on TTTS mortality and morbidity rates.

- Likelihood of being informed of threat of TTTS to MCDA pregnancy
 - White patients > Non-white patients
 - Privately insured patients > Publicly insured patients
- Likelihood of single loss outcome
 - White patients << Non-white patients
- Likelihood of double survivor outcome
 - White patients >> Non-white patients

Efforts must be made to maximize patients' understanding of all ramifications of their MCDA pregnancies, including possible sequelae and surveillance requirements

Despite an abundance of evidence regarding outcomes of MCDA pregnancies complicated by TTTS, there is a dearth of literature surrounding the role of sociodemographic factors in these outcomes. More studies are needed that examine this correlation so efforts to improve disparities can be better guided.



EPIC .PHRASE

BBonMCDAcounseling

Description: MCDA plan and counseling

The patient was counseled on her diagnosis of a monochorionic-diamniotic twin pregnancy. It was explained in plain language that this means there is an amniotic sac individual to each fetus, but one shared placenta. She was advised of associated risks and that delivery will be planned between 34 – 37 6/7 weeks gestation. The following was discussed regarding prenatal management, including plans for ultrasound and delivery.

- [] ASA 81 mg daily (initiate between 12-28w, optimally start <16w)
- [] Fetal echo 18-22 wks
- [] Fetal growths q4 wks starting at 24 wks
- [] Serial cervical lengths from 16-24w q2w
- [] Antenatal testing q2 wks from 16-32w, then weekly until delivery
- [] MOD counseling, including risks of breech extraction, combined delivery
- [] Delivery between 34 to 37+6 wks
- [] Delivery at CHONY



CODING AND BILLING

- 030.03 Twin pregnancy, monochorionic/diamniotic
- 030.031 Twin pregnancy, monochorionic/diamniotic, first trimester
- 030.032 Twin pregnancy, monochorionic/diamniotic, second trimester
- 030.033 Twin pregnancy, monochorionic/diamniotic, third trimester
- 030.039 Twin pregnancy, monochorionic/diamniotic, unsp trimester



EVIDENCE

References

- Seidel, S.L. *Monochorionic Twins. SASGOG Pearls of Excellence*. Moore Simas, TA, ed. The Society for Academic Specialists in General Obstetrics and Gynecology. 2016 [cited June 15, 2020]. Retrieved from: <https://excellence.org/list-of-pearls/monochorionic-twins/>
- Multifetal gestations: twin, triplet, and higher-order multifetal pregnancies. Practice Bulletin No. 169. American College of Obstetricians and Gynecologists. *Obstet Gynecol* 2016;128:e131–46.
- Simpson, L.L., 2015. What you need to know when managing twins: 10 key facts. *Obstetrics and Gynecology Clinics*, 42(2), pp.225-239.
- Simpson, L.L. and Society for Maternal-Fetal Medicine (SMFM), 2013. Twin-twin transfusion syndrome. *American Journal of Obstetrics and Gynecology*, 208(1), pp.3-18.
- Khalil, A., Rodgers, M., Baschat, A., Bhide, A., Gratacos, E., Hecher, K., Kilby, M.D., Lewi, L., Nicolaides, K.H., Oepkes, D. and Raine-Fenning, N., 2016. ISUOG Practice Guidelines: role of ultrasound in twin pregnancy. *Ultrasound in Obstetrics & Gynecology*, 47(2), pp.247-263.
- Fischbein, R., Nicholas, L., Aultman, J., Baughman, K. and Falletta, L., 2018. Twin-twin transfusion syndrome screening and diagnosis in the United States: A triangulation design of patient experiences. *PloS one*, 13(7), p.e0200087.
- Nicholas L. An Examination of the Effects of Current Obstetrical Opinions, Diagnostic and Practice Trends in the Management of Twin to Twin Transfusion Syndrome Patients. In: Blair SL, McCormick JH, editors. *Fam. Heal. Evol. Needs, Responsib. Exp. (Contemporary Perspect. Fam. Res. Vol. 8B)*. Bingley, England: Emerald Group Publishing Limited; 2014. p. 169–222

