

ADNEXAL MASSES IN REPRODUCTIVE AGED WOMEN

Week 61


Prepared by: **Devon Rupley, MD**

With SDH and .phrase slides by Chloé Altchek, MS4

Reading Assignment:

Management of Adnexal Cysts.

Pearls of Excellence



LEARNING OBJECTIVES



- To review the differential for adnexal masses in reproductive age women
- To determine the diagnostic approach towards patients with adnexal masses
- To understand the management for the most common adnexal masses in this population



CASE VIGNETTE

- Ms. MA is a 23 yo G0 woman presenting to clinic for follow up after an ER visit for a recently treated appendicitis showed an incidental finding of a 4 cm left ovarian mass on CT scan
 - She does not have the report or images from the ER visit, but was told to “follow up with a Gyn in a few weeks”



FOCUSED HISTORY

HPI: Today she feels well with no complaints. Reports normal monthly menses, LMP 3 weeks ago, lasted 4 days with light bleeding. She is sexually active with one male partner, notes some mild right-sided abdominal discomfort with intercourse. She is using condoms for contraception. She denies inter-menstrual bleeding, abnormal discharge, pelvic pain. ROS otherwise negative.

- **POBH:** Nulliparous
- **PGynH:** Denies STIs, abnormal paps, fibroids, cysts; age of menarche 13, nml cycles
- **PMH:** Mild intermittent asthma
- **PSH:** LSC Appendectomy 1 month ago
- **FH:** Denies
- **SH:** Soc EtOH (1-2 drinks/wk), denies tob/drug use; works as a barista, lives with roommates, feels safe in apt, denies DV.
- **Meds:** Denies
- **All:** NKDA



PERTINENT PHYSICAL EXAM FINDINGS

Vital Signs: 105/70, P 67, RR 16, O2 98%, T 37.0

- **Gen:** NAD, well appearing
- **HEENT:** Clear oropharynx
- **Chest:** CTAB
- **Thyroid:** No thyromegaly
- **CVS:** RRR
- **Abd:** Soft, NT, 3 well healed port incisions
- **Pelvic:** Normal external genitalia, scant physiologic discharge, no cervical lesions, no CMT, AV, small mobile uterus, some fullness in right adnexa approx 5 cm, very mildly tender
- **Ext:** WWP



ADNEXAL MASSES IN REPRODUCTIVE AGED WOMEN

- **How common are adnexal masses in reproductive aged women?**
 - Very common. Approximately **5-10% of asymptomatic women** age 25-40 will have an adnexal lesion on imaging at any time
- **Are most adnexal masses in reproductive aged women benign or malignant?**
 - Most are benign
 - Incidence of ovarian neoplasm increases with age:
 - **1.8-2.2**/100,000 for age 20-29
 - **3.1-5.1**/100,000 for age 30-39
 - **9.0-15.2**/100,000 for age 40-49
- **What are the most commonly occurring adnexal masses in menstruating women?**
 - **Physiologic** or **functional cysts** - resolve in 6-8 weeks

WHAT IS YOUR DIFFERENTIAL FOR MS. MA?

Stratify by location....

- **Ovarian**

- **Benign**

- Simple cyst
- Functional cyst (corpus luteum)
- Serous or mucinous cystadenoma
- Endometrioma
- Dermoid

- **Malignant**

- Epithelial carcinoma
- Malignant germ cell/ or sex cord-stromal tumor

- **Tubal**

- Ectopic pregnancy
- Hydrosalpinx/ TOA
- Paraovarian/ paratubal cyst
- Tubal neoplasm



- **Uterus**

- Uterine leiomyoma (pedunculated)

- **Non-GYN**

- Constipation
- Diverticular abscess
- Pelvic abscess
- Pelvic kidney
- Non-GYN primary malignancy
- Metastasis



WHAT ARE YOUR NEXT STEPS?



Obtain more history

Evaluate for:

- History of similar episodes of pain, mid-cycle pain, or association with intercourse/ vigorous exercise point towards **functional/ benign cysts**
- Infectious symptoms: fever, discharge, history of STD's, multiple partners would increase likelihood for **TOA/pelvic abscess**
- Unintended weight loss, swelling, abnormal bleeding increase suspicion for **malignancy**



WHAT ARE YOUR NEXT DIAGNOSTIC STEPS?

- Pregnancy test
- Pelvic ultrasound
- Counseling on torsion precautions (if concerned for ovarian cyst)

- If patient is acutely ill or you have concern for torsion, send to ER for expedited work up



VectorStock.com/12182



MANAGEMENT

Depends on patient presentation and characteristics of the mass

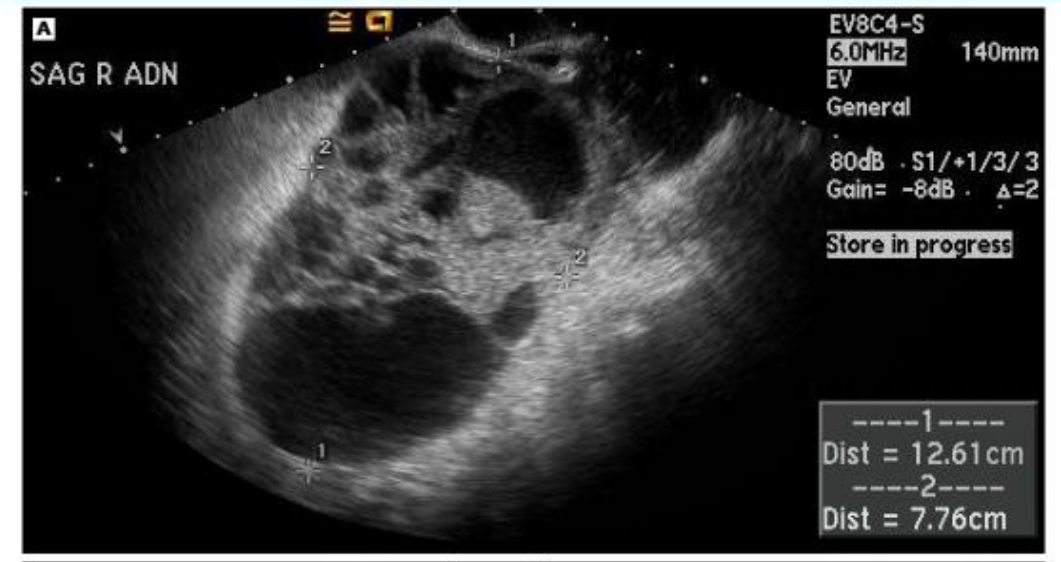- Acute pain/ clinical instability: **urgent surgical intervention** to rule out and treat **ectopic pregnancy**, **ovarian torsion**, or **ruptured hemorrhagic cyst**
 - If patient clinically stable and most likely diagnosis is **ruptured hemorrhagic cyst**, can consider observation with serial CBCs and abdominal exams
- If **simple appearing cyst**, most will regress spontaneously over 6-8 weeks
 - Recommend observation with reimaging in 8-12 weeks with torsion precautions
- If findings concerning for **malignancy**, send tumor markers and refer to gyn-onc
 - **CA-125**, **CEA**, **CA 19-9** for epithelial ovarian cancer
 - For reproductive aged women **AFP**, **LDH**, **inhibin** and **HCG** are helpful in non-epithelial cancers

ULTRASOUND FINDINGS

- **Ultrasound findings likely benign (B-features):**
 - Unilocular cyst, any size
 - Solid components not present or less than 7 mm
 - Presence of acoustic shadowing
 - Smooth multilocular cyst less than 10 cm
 - No blood flow to cyst
- **Ultrasound findings concerning for malignancy (M-features):**
 - Nodular or papillary excrescences
 - Calcifications
 - Thick septations (>2 mm)
 - Presence of ascites
 - Color flow to solid components

© 2019 UpToDate, Inc. and/or its affiliates. All Rights Reserved.

Sonographic appearance of ovarian cystadenocarcinoma



MANAGEMENT CONTINUED...

Consider **surgical management** of **benign lesions** if:

- Persistent pain or symptoms
- Imaging c/f endometrioma and patient with infertility
- High risk for ovarian torsion:
 - **Size > 5cm**
 - 80% of patients with torsion have cyst > 5 cm
 - **Dermoid cyst**
 - 5-15% risk of torsion
 - **Pregnancy**
 - 10-22% of ovarian torsion occurs in pregnancy



BACK TO THE PATIENT

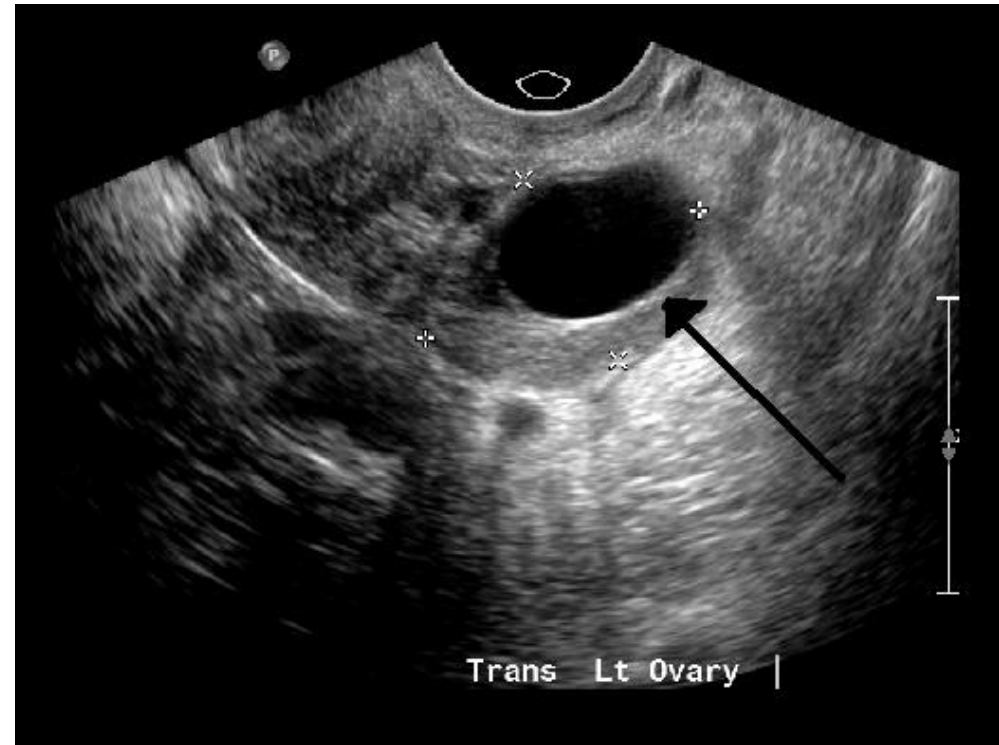
Ms. MA returns after pelvic sono with imaging showing a 2 cm left pelvic mass as below:

What is her diagnosis?

Simple ovarian cyst

Recommended management?

Observation

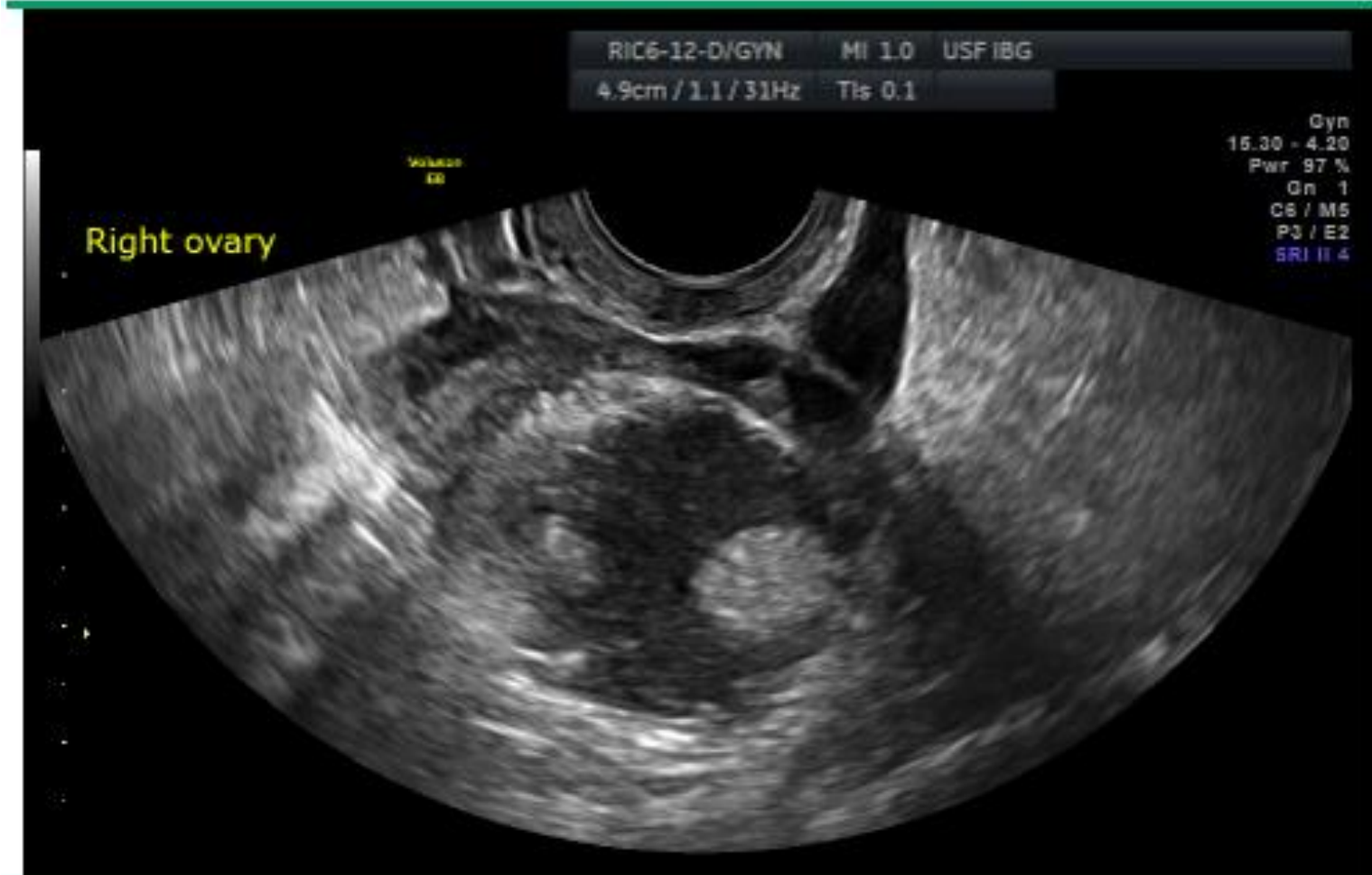


https://en.wikipedia.org/wiki/Ovarian_cyst

OTHER COMMON BENIGN ULTRASOUND FINDINGS

© 2019 UpToDate, Inc. and/or its affiliates. All Rights Reserved.

Benign mature ovarian teratoma (dermoid cyst) on ultrasound



Transvaginal ultrasound of a mature teratoma in the ovary containing heterogeneous contents, which often shadow. It is round and well circumscribed. This image contains the "ovarian crescent" sign, which is a rim of normal-appearing ovary with follicles. These features suggest a benign cyst.



SOCIAL DETERMINANTS OF HEALTH

Disparities in timely diagnosis of ovarian cancer

African American women are 40% more likely to be diagnosed with late-stage disease than white women*

African American women are less likely to have regular care from a primary care provider

African American women are 25% more likely to experience a miscommunication with their provider

As providers, what are the modifiable variables that we can mitigate?

Uninsured or underinsured patients are 50% less likely to be diagnosed with early-stage epithelial ovarian cancer than those with private insurance

Lower ovarian cancer survival rates in African American women and women of low socioeconomic status compared to white women

African American women are more likely to delay medical care due to financial reasons



*adjusting for demographic and tumor factors

EPIC .PHRASE

.BBonAdnexalmassWU

Description: Adnexal mass workup

We discussed the diagnosis of adnexal mass and the most common etiologies based on the location of the mass, including simple cyst, functional cyst (corpus luteum), serous or mucinous cystadenoma, endometrioma, dermoid cyst, epithelial carcinoma, malignant germ cell tumor, and sex cord-stromal tumor for ovarian masses; ectopic pregnancy, hydrosalpinx/ TOA, paraovarian/ paratubal cyst, tubal neoplasm for tubal masses; uterine leiomyoma (pedunculated) for uterine masses; and constipation, diverticular abscess, pelvic abscess, pelvic kidney, non-GYN primary malignancy, and metastasis for non-GYN adnexal masses. A thorough evaluation was started today, including ultrasound, pregnancy test, and CBC. ***If malignant features: CA-125, CEA, CA 19-9, consider AFP, LDH, inhibin and B-HCG in reproductive aged women. The patient was counseled regarding emergency signs or symptoms for torsion such as sudden development of severe pain, worsening nausea or vomiting, or development of fevers and chills.



BILLING AND CODING

- R19.09: other intra-abdominal and pelvic swelling, mass and lump
- N83.20: unspecified ovarian cyst
- R10.2: pelvic and perineal pain



EVIDENCE

- References

- Evaluation and Management of Adnexal Masses. Practice Bulletin No. 174. American College of Obstetricians and Gynecologists. 2016.
- Muto MG. Approach to the patient with an adnexal mass. Uptodate. Feb 23, 2018.
- Muto MG. Management of an adnexal mass. Uptodate. Sep 24, 2018.
- Gruenigen VE. Management of Adnexal Cysts. Pearls of Excellence. Sep 9, 2010.
- Ci H, Hong MK, Ding DC. A review of ovarian torsion. *Tzu Chi Medical Journal*. 2017. Sep; 29(3): 143-147.
- Patel MD. Ultrasound differentiation of benign versus malignant adnexal masses. Uptodate. May 14, 2019
- Morris CR, Sands MT, Smith LH. Ovarian cancer: predictors of early-stage diagnosis. *Cancer Causes Control*. 2010;21(8):1203-1211. doi:10.1007/s10552-010-9547-0
- Karanth S, Fowler ME, Mao X, et al. Race, Socioeconomic Status, and Health-Care Access Disparities in Ovarian Cancer Treatment and Mortality: Systematic Review and Meta-Analysis. *JNCI Cancer Spectr*. 2019;3(4):pkz084. Published 2019 Oct 9. doi:10.1093/jncics/pkz084
- Healthcare Research and Quality (2007) National Healthcare Disparities Report. Rockville, MD: U.S. Department of Health and Human Services, Agency for Healthcare Research and Quality; February 2008. AHRQ Pub. No. 08-0041

